

Assessment of Brain Injury Using Portable, Low-Field Magnetic Resonance Imaging at the Bedside of Critically Ill Patients

Kevin N. Sheth, MD; Mercy H. Mazurek, BS; Matthew M. Yuen, BA; Bradley A. Cahn, BS; Jill T. Shah, BA; Adrienne Ward, RN; Jennifer A. Kim, MD, PhD; Emily J. Gilmore, MD; Guido J. Falcone, MD, ScD, MPH; Nils Petersen, MD, PhD; Kevin T. Gobeske, MD, PhD, MPH; Firas Kaddouh, MD; David Y. Hwang, MD; Joseph Schindler, MD; Lauren Sansing, MD, MS; Charles Matouk, MD; Jonathan Rothberg, PhD; Gordon Sze, MD; Jonathan Siner, MD; Matthew S. Rosen, PhD; Serena Spudich, MD, MA; W. Taylor Kimberly, MD, PhD

IMPORTANCE Neuroimaging is a key step in the clinical evaluation of brain injury. Conventional magnetic resonance imaging (MRI) systems operate at high-strength magnetic fields (1.5-3 T) that require strict, access-controlled environments. Limited access to timely neuroimaging remains a key structural barrier to effectively monitor the occurrence and progression of neurological injury in intensive care settings. Recent advances in low-field MRI technology have allowed for the acquisition of clinically meaningful imaging outside of radiology suites and in the presence of ferromagnetic materials at the bedside.

OBJECTIVE To perform an assessment of brain injury in critically ill patients in intensive care unit settings, using a portable, low-field MRI device at the bedside.

DESIGN, SETTING, AND PARTICIPANTS This was a prospective, single-center cohort study of 50 patients admitted to the neuroscience or coronavirus disease 2019 (COVID-19) intensive care units at Yale New Haven Hospital in New Haven, Connecticut, from October 30, 2019, to May 20, 2020. Patients were eligible if they presented with neurological injury or alteration, no contraindications for conventional MRI, and a body habitus not exceeding the scanner's 30-cm vertical opening. Diagnosis of COVID-19 was determined by positive severe acute respiratory syndrome coronavirus 2 polymerase chain reaction nasopharyngeal swab result.

EXPOSURES Portable MRI in an intensive care unit room.

MAIN OUTCOMES AND MEASURES Demographic, clinical, radiological, and treatment data were collected and analyzed. Brain imaging findings are described.

RESULTS Point-of-care MRI examinations were performed on 50 patients (16 women [32%]; mean [SD] age, 59 [12] years [range, 20-89 years]). Patients presented with ischemic stroke (n = 9), hemorrhagic stroke (n = 12), subarachnoid hemorrhage (n = 2), traumatic brain injury (n = 3), brain tumor (n = 4), and COVID-19 with altered mental status (n = 20). Examinations were acquired at a median of 5 (range, 0-37) days after intensive care unit admission. Diagnostic-grade T1-weighted, T2-weighted, T2 fluid-attenuated inversion recovery, and diffusion-weighted imaging sequences were obtained for 37, 48, 45, and 32 patients, respectively. Neuroimaging findings were detected in 29 of 30 patients who did not have COVID-19 (97%), and 8 of 20 patients with COVID-19 (40%) demonstrated abnormalities. There were no adverse events or complications during deployment of the portable MRI or scanning in an intensive care unit room.

CONCLUSIONS AND RELEVANCE This single-center series of patients with critical illness in an intensive care setting demonstrated the feasibility of low-field, portable MRI. These findings demonstrate the potential role of portable MRI to obtain neuroimaging in complex clinical care settings.

Author Affiliations: Author affiliations are listed at the end of this article.

Corresponding Author: Kevin N. Sheth, MD, Yale University School of Medicine, Department of Neurology, 15 York St, LLCI Room 1003C, PO Box 208018, New Haven, CT 06520 (kevin.sheth@yale.edu) and W. Taylor Kimberly, MD, PhD, Division of Neurocritical Care, Department of Neurology, Massachusetts General Hospital, 55 Fruit St, Lunder 644, Mailcode: WACC 8-835, Boston, MA 02114 (wtkimberly@mgh.harvard.edu).

JAMA Neurol. doi:10.1001/jamaneurol.2020.3263
Published online September 8, 2020.

Advanced brain imaging is a cornerstone of neurological diagnosis. Conventional magnetic resonance imaging (MRI) systems operate through high-strength magnetic fields (1.5-3 T) that require strict, access-controlled environments, rigid safety precautions, and highly trained technicians.¹ As a result, the traditional neuroimaging workflow requires patient transport to dedicated hospital imaging suites. This operational paradigm has been necessary to ensure patient safety in and around high-field scanners but has rendered MRI largely inaccessible in the setting of critical illness.²⁻⁶

In patients admitted to an intensive care unit, there are numerous risks involved in transportation to imaging suites, including compromise of monitoring equipment, venous access limitations, and risk of endotracheal tube displacement.^{3,4} Furthermore, in patients who are critically ill with infectious diseases such as coronavirus disease 2019 (COVID-19), the highly contagious nature of the disease can impose considerable limitations on transportation to and decontamination of traditional imaging suites. Recent advances in MRI technology have allowed for data acquisition at low magnetic field strength.¹ The MRI scanners operating at low field strength allow for open geometry designs that can ease patient handling and positioning and are compatible with nearby ferromagnetic materials, enabling scanning outside of the controlled access environment of an MRI suite.¹

We recently developed and deployed a novel bedside neuroimaging solution, for which this is our first clinical report. We investigated patients with neurological injury or alteration using a low-field (0.064-T) portable MRI device at the bedside in neuroscience intensive care units (ICUs) and COVID-19 ICUs. This point-of-care (POC) MRI used no cryogenics and plugged into a single, 110-V, 15-A standard power outlet. The

Key Points

Question Can brain injury in patients who are critically ill be assessed using a novel portable, low-field magnetic resonance imaging (MRI) device at the bedside in an intensive care setting?

Findings In this cohort study of a series of 50 patients imaged with a portable, bedside MRI device, including patients with ischemic stroke, hemorrhagic stroke, subarachnoid hemorrhage, traumatic brain injury, brain tumor, and COVID-19 and altered mental status, abnormal neuroimaging findings were detected in 29 of 30 patients without COVID-19 (97%); 8 of 20 patients with COVID-19 (40%) demonstrated abnormalities. There were no adverse events or complications.

Meaning This study demonstrates the capability of low-field, portable MRI to obtain neuroimaging at the bedside in intensive care settings.

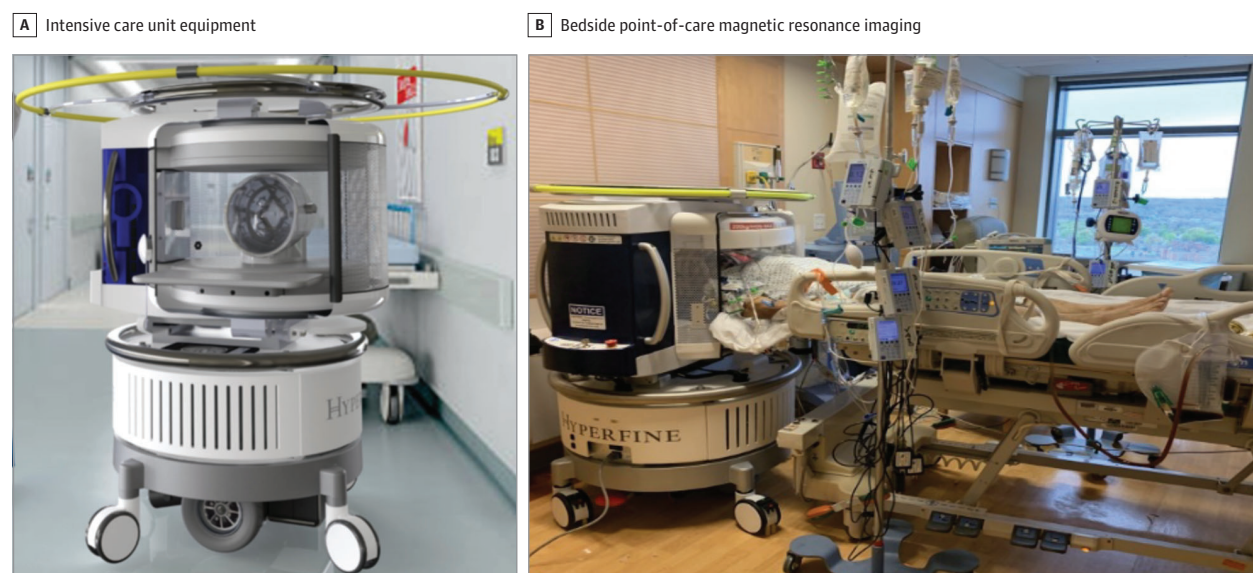device dimensions rendered it maneuverable within the confines of an ICU patient room (Figure 1). A self-contained motor and driving capability facilitated the deployment of a single device across the institution. The 5-Gauss (0.0005-T) safety perimeter had a radius of 79 cm from the center of the magnet. This work aimed to demonstrate the potential role of low-field, portable MRI to obtain bedside neuroimaging in an ICU setting.

Methods

Study Setting and Participants

The study was performed at Yale New Haven Hospital in New Haven, Connecticut, from October 2019 through June 2020 under an institutional review board research protocol approved

Figure 1. Point-of-Care Magnetic Resonance Images (0.064 T) in an Intensive Care Unit Room



All intensive care unit equipment, including ventilators, pumps, and monitoring devices, as well as the point-of-care magnetic resonance image operator and bedside nurse, remained in the room. All equipment was operational during scanning.

by Yale Human Research Protection Program. For patients admitted to the neuroscience ICU, the POC MRI device operated with an investigational device exemption, and patient informed consent was obtained under the approved institutional review board protocol. For patients admitted to the COVID-19 ICUs, the MRI device received US Food and Drug Administration clearance during the COVID-19 public health emergency,⁷ and images were acquired as part of clinical care. As a result, patient informed consent was obtained for the first 6 patients with COVID-19 under the approved protocol but waived for the subsequent 14 patients with COVID-19.

Patients were screened for eligibility based on admission diagnosis and clinical examination. For patients presenting to the neuroscience ICU, a diagnosis of an acute brain injury, as determined by a clinical radiographic reading, constituted study eligibility. For patients presenting to the COVID-19 ICUs, any neurological alteration appreciated during clinical examination (eg, altered mental status or acute brain injury, if the patient received conventional neuroimaging) constituted eligibility for study inclusion. Exclusion criteria included a patient body size exceeding the scanner's 30-cm vertical opening or the presence of at least 1 of the following contraindications to conventional MRI evaluation: cardiac pacemakers or defibrillators, intravenous medication pumps, insulin pumps, deep brain stimulators, vagus nerve stimulators, cochlear implants, pregnancy, ongoing extracorporeal membrane oxygenation treatment, and cardiorespiratory instability. Diagnosis of COVID-19 was determined by a positive severe acute respiratory syndrome coronavirus 2 polymerase chain reaction nasopharyngeal swab result.

Because of the low field strength, ferromagnetic equipment in the hospital room was not removed, including vital sign monitors, intravenous infusion pumps, ventilators, compressed gas tanks, and dialysis machines. A hospital-approved disinfectant was used to clean the device following each scan. For patients who did not receive conventional neuroimaging, POC MRI examinations were interpreted by a board-certified neuroradiologist (G.S.). Conventional scans were interpreted by staff neuroradiologists.

Imaging Parameters

The POC MRI examinations were performed at the bedside using a prototype 0.064-T MRI system (with Mk 1.2 RC6.3-7.2 software and Mk 1.6 POC MRI RC8.0.2 software [Hyperfine Research Inc]). Examinations were acquired using an 8-channel head coil. The POC MRI used a biplanar, 3-axis gradient system with a peak amplitude of 26 mT/m (on the z-axis) and 25 mT/m (on the x-axis and y-axis). Scan parameters were controlled using a computer interface (iPad Pro, third generation; Apple). Available pulse sequences included T1-weighted (T1W), T2-weighted (T2W), fluid-attenuated inversion recovery (FLAIR), and diffusion-weighted imaging (DWI) with apparent diffusion coefficient (ADC) mapping. Examinations were acquired in the axial, sagittal, and coronal planes. The following pulse 3-dimensional sequences were used: T1W fast spin echo (FSE) (repetition time [TR], 1500 milliseconds; time to echo [TE], 6 milliseconds; inversion time [TI], 300 milliseconds; $1.5 \times 1.5 \times 5$ -mm resolution; 36 slices); T2W FSE

(TR, 2200 milliseconds; TE, 253 milliseconds; $1.5 \times 1.5 \times 5$ -mm resolution; 36 slices); T2W FLAIR FSE (TR, 4000 milliseconds; TE, 228 milliseconds; TI, 1400 milliseconds; $1.6 \times 1.6 \times 5$ -mm resolution; 36 slices); and DWI FSE (TR, 1000 milliseconds; TE, 100 milliseconds; $b = 800$ seconds/mm²; $2.4 \times 2.4 \times 6$ -mm resolution; 30 slices).

The POC MRI examinations were available on a cloud-based imaging viewer immediately after scan completion (Hyperfine Purview). Patient demographics, clinical course characteristics, and available conventional neuroimaging were obtained from the electronic medical records. The κ statistic was computed using R software version 3.3.6 (R Foundation for Statistical Computing), with statistical significance set at $P < .05$.

Results

Characteristics of Patient Cohort With Critical Illness

We obtained POC MRI examinations for 50 patients (16 women [32%]; mean [SD] age, 59 [12] years [range, 20-89 years]) (Table). Patients presented with ischemic stroke ($n = 9$), hemorrhagic stroke ($n = 12$), subarachnoid hemorrhage ($n = 2$), traumatic brain injury ($n = 3$), brain tumor ($n = 4$), and COVID-19 infection with altered mental status ($n = 20$). Examinations were acquired at a median of 5 (range, 0-37) days since ICU admission. Three patients were imaged at 2 serial points, and 1 patient was imaged at 4 serial points. There were no adverse events or complications during deployment of the POC MRI or scanning in an ICU room.

For patients with COVID-19 ($n = 20$), the median Richmond Agitation Sedation Scale score at time of scan was -3 (range, -5 to 0). Fifteen patients were sedated and 4 were paralyzed at the time of scanning. For the duration of the POC MRI examination, 18 patients were mechanically ventilated (14 with endotracheal intubation and 4 with tracheostomy), and 1 patient required high-flow oxygen. Three patients were receiving continuous kidney replacement therapy.

Neuroimaging Parameters

Diagnostic-grade T1W, T2W, T2 FLAIR, and DWI sequences were obtained for 37, 48, 45, and 32 patients, respectively. The mean examination time was 35 minutes and 40 seconds. Mean axial sequence scanning times were as follows: T1W, 4 minutes and 54 seconds; T2W, 7 minutes and 3 seconds; FLAIR, 9 minutes and 31 seconds; and DWI with b set to 0 seconds/mm² to calculate an ADC map, 9 minutes and 4 seconds.

Neuroimaging Findings

In patients without COVID-19 ($n = 30$), neuroimaging findings were detected in 29 cases (97%). Twenty-nine patients (97%) also received conventional imaging (computed tomography, 6 patients; MRI, 23 patients). All POC MRI findings were in agreement with available conventional radiology reports, except that 1 patient had a diffuse subarachnoid hemorrhage that was not observed on POC MRI ($\kappa = 0.65$; $P < .001$). Figure 2A shows POC MRI scans of a patient presenting to the neuroscience ICU with a left occipital hemorrhage, in agree-

Table. Patient Demographics and Clinical Characteristics

Characteristic	Patients, No. (%)				
	Stroke ^a	Traumatic brain injury	Tumor	COVID-19	All participants ^b
Total No.	23	3	4	20	50
Age, mean (SD), y	60 (13)	61 (10)	43 (15)	60 (8)	59 (12)
Female	11 (48)	1 (33)	1 (25)	3 (15)	16 (32)
BMI, mean (SD)	27 (5)	24 (3)	24 (1)	28 (6)	27 (5)
Race					
White	14 (61)	2 (67)	3 (75)	5 (25)	24 (48)
Black or African American	5 (22)	0 (0)	0 (0)	5 (25)	10 (20)
Asian	3 (13)	0 (0)	1 (25)	0 (0)	4 (8)
Unknown	0 (0)	1 (33)	0 (0)	0 (0)	1 (2)
Other	1 (4)	0 (0)	0 (0)	10 (50)	11 (22)
Medical history					
Prior stroke	3 (13)	1 (33)	0 (0)	1 (5)	5 (10)
Hypertension	12 (52)	2 (67)	3 (75)	9 (45)	26 (52)
Hyperlipidemia	10 (43)	2 (67)	1 (25)	7 (35)	19 (38)
Diabetes	3 (13)	1 (33)	1 (25)	9 (45)	2 (4)
Obesity	5 (22)	0 (0)	0 (0)	7 (35)	13 (26)
Coronary artery disease	3 (13)	0 (0)	0 (0)	1 (5)	12 (24)
Time measurements, median (range)					
LKN to examination, h	52 (13 to 222)	84 (48 to 120) ^c	NA	NA	52 (13 to 222) ^c
Admission to examination, d	2 (0 to 16)	2 (2 to 3)	2 (1 to 2)	25 (5 to 37)	5 (0 to 37)
Cognitive scores, median (range)					
GCS at examination ^d	15 (9 to 15)	15	15	6 (3 to 14)	13 (3 to 15)
NIHSS at examination ^d	2 (0 to 19)	NA	NA	NA	2 (0 to 19)
RASS at examination ^d	NA	NA	NA	-3 (0 to -5)	-3 (0 to -5)
Discharge functional outcome by mRS score	3 (0 to 6)	3 (0 to 3)	1 (1 to 4)	5 (1 to 6)	3 (0 to 6)

Abbreviations: BMI, body mass index (calculated as weight in kilograms divided by height in meters squared); COVID-19, coronavirus disease 2019; GCS, Glasgow Coma Scale; LKN, last known normal; mRS, modified Rankin Scale; NA, not applicable; NIHSS, National Institutes of Health Stroke Scale; RASS, Richmond Agitation and Sedation Scale.

^a Stroke includes acute ischemic stroke, intraparenchymal hemorrhage, and subarachnoid hemorrhage.

^b Percentages may not total to 100% because of rounding.

^c LKN was not available for 1 individual.

^d Closest values to point-of-care magnetic resonance imaging examination.

ment with a conventional 1.5-T MRI. Figure 2B illustrates a previously undetected, small-volume infarction in a patient with cardiac arrest who was too unstable to be transported to conventional imaging.

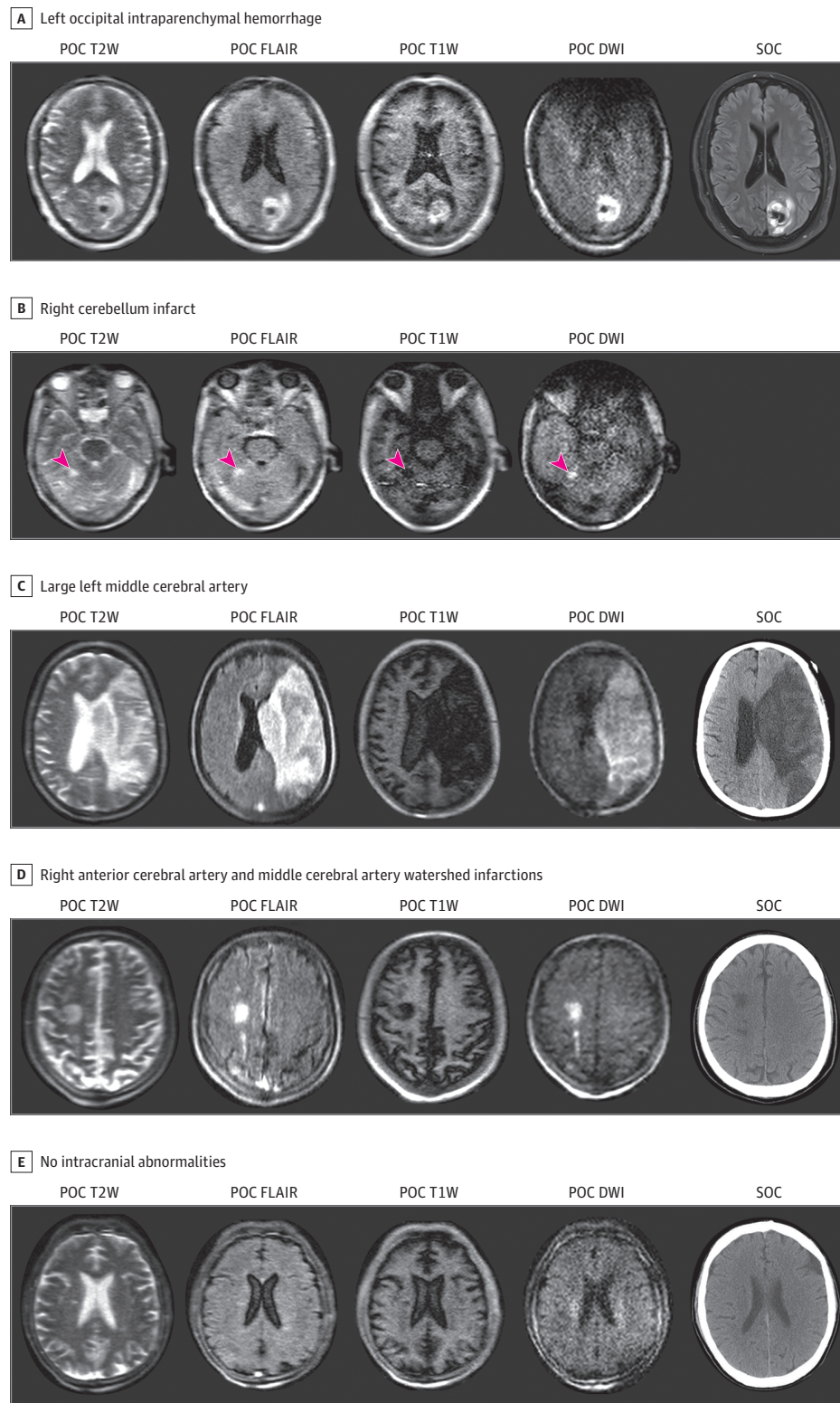
For patients with COVID-19 (n = 20), neuroimaging findings were observed in 8 patients (40%): an intracranial hemorrhage was found in 1 patient, cerebral infarction in 3, diffuse cerebral edema in 1, and leukoencephalopathy in 3. Eleven patients (55%) received conventional neuroimaging (computed tomography, 8; MRI, 3). Of the patients who received conventional imaging, all POC MRI findings were in agreement with conventional radiology reports. Figure 2C shows the images from a patient who was paralyzed and sedated and had a previously undetected, large hemispheric infarction of the left middle cerebral artery territory. Conventional noncontrast computed tomography (NCCT) following bedside MRI examination confirmed the POC MRI finding. Figure 2D illustrates an example of a smaller-volume infarction, further demonstrating the capability of POC MRI to detect both small and large ischemic strokes; this infarction was confirmed by available conventional NCCT. Figure 2E shows the images from a patient with no intracranial abnormalities, in agreement with conventional NCCT findings.

Discussion

We report advanced neuroimaging in ICUs using a novel approach for the bedside assessment of intracranial pathology. These findings demonstrate for the first time (to our knowledge) the deployment of a portable MRI to the bedside of patients with critical illness. In acute neurological settings, it is well established that noninvasive, time-sensitive neuroimaging is the cornerstone of triage and treatment pathways. For ICUs, access to MRI is limited, and the risks of transporting patients with critical illness are well documented.²⁻⁶ Risks to inpatient populations and clinicians are potentially increased when considering infection control issues, as illustrated by the COVID-19 pandemic. This report helps fill an important gap in the topic of obtaining neuroimaging for patients with critical illness and potential neuropathology.

Recent advances in low-magnetic field MRI have made the current solution possible, whereby an MRI scanner can safely enter the bedside clinical environment. Operation at 64 mT has enabling advantages, including compatibility with nearby ferromagnetic materials.¹ Additionally, the scanner uses a permanent magnet that obviates the need for any cooling. The low

Figure 2. Examples of Point-of-Care (POC) Magnetic Resonance Imaging (MRI) vs Standard-of-Care (SOC) Imaging in 5 Patients



A, A patient in their 40s with left occipital intraparenchymal hemorrhage. B, A patient in their 40s admitted for cardiac arrest and found to have fixed pupils but to be too unstable to obtain SOC imaging; a POC MRI demonstrates a right cerebellum infarct (arrowheads). C, A patient in their 50s presenting with altered mental status at the time of scanning. A POC MRI demonstrates large left middle cerebral artery infarct with hemorrhagic transformation. D, A patient in their 50s who was sedated and not tracking or following commands at the time of the scan. A POC MRI demonstrates a right anterior cerebral artery–middle cerebral artery watershed infarction. E, A patient in their 60s presenting with altered mental status at the time of scanning. A POC MRI shows no intracranial abnormalities. Available SOC imaging (3 computed tomography images and 1 MRI scan) further validated each of these POC MRI findings. DWI indicates diffusion-weighted imaging; FLAIR, fluid-attenuated inversion recovery; T1W, T1-weighted; T2W, T2-weighted.

power consumption of the scanner (<1650 W) means that the scanner can operate directly from the standard electrical power available in any room.

Neurological complications and neurotropism have been reported in patients with COVID-19, including headache, altered mental status, acute cerebrovascular disease,

encephalopathy, leptomeningeal enhancement, and seizures.⁸⁻¹⁰ However, reports on neurologic complications in patients who are critically ill with COVID-19 have been hampered by a paucity of neuroimaging. Patients with severe COVID-19 experience multiple organ injuries,¹¹ often requiring the sustained use of mechanical ventilation and dialysis with continuous kidney replacement therapy.¹² These patients with severe illness are most in need of MRIs because of the increased risk of neurological sequelae and frequent sedation or paralysis for ventilator management, the second of which prevents routine assessment of neurological status.¹² We obtained neuroimaging in 20 patients with COVID-19 requiring ventilation, 3 of whom also required continuous kidney replacement therapy, and observed neurological findings in 8 of 20 patients (40%). This experience illustrates an example of how deploying bedside MRI into complex clinical settings can permit neuroimaging in an otherwise restricted setting.

Limitations

The main limitations of this study are the single-center design and the limited number of patients imaged. Prospective multicenter studies in which POC MRI diagnostic results are compared with conventional computed tomography or MRI

results for discrete pathologies are necessary for further validation. In addition, this was a cross-sectional study in which patients were imaged at variable points in their hospital course. Nevertheless, the portability, image quality, and ease of operation of the POC MRI have addressed a critical neurodiagnostic need in patients with severe illness.

Conclusions

Future studies should assess brain pathology at fixed points in a multicenter validation study. The availability of a bedside POC MRI would also facilitate serial measurements, potentially providing insight into the frequency of neurological pathology, as well as its time course. The temporal profile becomes particularly relevant for the design of potential interventional studies aimed at preventing neurological complications.

In conclusion, this experience demonstrates that low-field, portable MRI can be deployed successfully into intensive care settings. This approach may hold promise for portable assessment of neurological injury in other scenarios, including the emergency department, mobile stroke units, and resource-limited environments.

ARTICLE INFORMATION

Accepted for Publication: July 17, 2020.

Published Online: September 8, 2020.
doi:10.1001/jamaneurol.2020.3263

Author Affiliations: Department of Neurology, Yale University School of Medicine, New Haven, Connecticut (Sheth, Mazurek, Yuen, Cahn, Shah, Kim, Gilmore, Falcone, Petersen, Gobeske, Kaddouh, Hwang, Schindler, Sansing); Neuroscience Intensive Care Unit, Yale New Haven Hospital, New Haven, Connecticut (Ward); Department of Neurosurgery, Yale School of Medicine, New Haven, Connecticut (Matouk); Department of Genetics, Yale University School of Medicine, New Haven, Connecticut (Rothberg); Hyperfine Research Inc, Guilford, Connecticut (Rothberg); Department of Radiology, Yale University School of Medicine, New Haven, Connecticut (Sze); Division of Pulmonology and Sleep Medicine, Department of Medicine, Yale University School of Medicine, New Haven, Connecticut (Siner); Athinoula A. Martinos Center for Biomedical Imaging, Massachusetts General Hospital, Charlestown (Rosen); Division of Neurology Infections & Global Neurology, Department of Neurology, Yale University School of Medicine, New Haven, Connecticut (Spudich); Division of Neurocritical Care, Department of Neurology, Massachusetts General Hospital, Boston (Kimberly).

Author Contributions: Dr Sheth had full access to all of the data in the study and takes responsibility for the integrity of the data and the accuracy of the data analysis. Dr Sheth is the principal investigator. Drs Sheth, Spudich, and Kimberly contributed equally.

Concept and design: Sheth, Mazurek, Yuen, Cahn, Rothberg, Rosen, Spudich, Kimberly.
Acquisition, analysis, or interpretation of data: Sheth, Mazurek, Yuen, Cahn, Shah, Ward, Kim,

Gilmore, Falcone, Petersen, Gobeske, Kaddouh, Hwang, Schindler, Sansing, Sze, Matouk, Siner, Spudich, Kimberly.

Drafting of the manuscript: Sheth, Mazurek, Yuen, Cahn, Schindler, Kimberly.

Critical revision of the manuscript for important intellectual content: Sheth, Mazurek, Yuen, Cahn, Shah, Ward, Kim, Gilmore, Falcone, Petersen, Gobeske, Kaddouh, Hwang, Rothberg, Sansing, Sze, Matouk, Siner, Rosen, Spudich.

Statistical analysis: Mazurek, Cahn.

Obtained funding: Sheth, Rosen, Kimberly.

Administrative, technical, or material support: Sheth, Yuen, Shah, Gobeske, Schindler, Rothberg, Sze, Siner, Rosen.

Supervision: Sheth, Petersen, Kaddouh, Rothberg, Matouk, Siner, Kimberly.

Other—facilitating collection of clinical data: Spudich.

Other—built and led team that developed all the technology: Rothberg.

Conflict of Interest Disclosures: Dr Sheth reported grants from the American Heart Association and Hyperfine Research Inc during the conduct of the study and grants from Bard, Biogen, and Novartis; personal fees from Zoll; and other support from Alva outside the submitted work. Dr Rothberg reported that, outside the submitted work, he and his children hold significant stock ownership in Hyperfine Research, which developed all the technology in this article; in addition, Dr Rothberg holds many patents, pending and issued, and is the founder and chairman of Hyperfine Research, the company that built the technology and wanted the technology to be used on coronavirus disease 2019 research. Dr Sansing reported personal fees from Genentech outside the submitted work. Dr Sze reported grants from American Heart Association during the conduct of the study. Dr Rosen reported grants from American Heart Association during the conduct of the study, personal fees from Hyperfine

Research Inc outside the submitted work, being a cofounder of Hyperfine Research Inc, and being listed as a coinventor on several pieces of Hyperfine intellectual property. Dr Spudich reported grants from the National Institutes of Health, National Institutes of Neurological Diseases and Stroke, and National Institutes of Mental Health outside the submitted work. Dr Kimberly reported grants from American Heart Association during the conduct of the study; grants and personal fees from Biogen and NControl Therapeutics outside the submitted work; and holding patent 16/486,687, pending and licensed. No other disclosures were reported.

Funding/Support: This study was supported by funding from the American Heart Association (Collaborative Science Award 17CSA3355004 [Drs Sheth, Kimberly, and Rosen]). The prototype device that was developed, deployed, and provided to Yale University was born out of an academic-industry collaboration in which the American Health Association grant supported the academic investigators. Dr Sheth is supported by the National Institutes of Health (grants U24NS107136, U24NS107215, R01NR018335, and U01NS106513) and the American Heart Association (grants 18TPA34170180 and 17CSA33550004) and a Hyperfine Research Inc research grant.

Role of the Funder/Sponsor: The funders had no role in the design and conduct of the study; collection, management, analysis, and interpretation of the data; preparation, review, or approval of the manuscript; and decision to submit the manuscript for publication.

REFERENCES

1. Sarracanie M, LaPierre CD, Salameh N, Waddington DEJ, Witzel T, Rosen MS. Low-cost high-performance MRI. *Sci Rep*. 2015;5(15177):15177. doi:10.1038/srep15177

2. Hricak H, Brenner DJ, Adelstein SJ, et al. Managing radiation use in medical imaging: a multifaceted challenge. *Radiology*. 2011;258(3):889-905. doi:10.1148/radiol.10101157
3. Agrawal S, Hulme SL, Hayward R, Brierley J. A Portable CT scanner in the pediatric intensive care unit decreases transfer-associated adverse events and staff disruption. *Eur J Trauma Emerg Surg*. 2010;36(4):346-352. doi:10.1007/s00068-009-9127-8
4. Peace K, Wilensky EM, Frangos S, et al. The use of a portable head CT scanner in the intensive care unit. *J Neurosci Nurs*. 2010;42(2):109-116. doi:10.1097/JNN.0b013e3181ce5c5b
5. Peace K, Maloney-Wilensky E, Frangos S, et al. Portable head CT scan and its effect on intracranial pressure, cerebral perfusion pressure, and brain oxygen. *J Neurosurg*. 2011;114(5):1479-1484. doi:10.3171/2010.11.JNSO91148
6. Brenner DJ, Hricak H. Radiation exposure from medical imaging: time to regulate? *JAMA*. 2010;304(2):208-209. doi:10.1001/jama.2010.973
7. US Food and Drug Administration. Enforcement policy for imaging systems during the coronavirus disease 2019 (COVID-19) public health emergency: guidance for industry and Food and Drug Administration staff. Published April 2020. Accessed July 30, 2020. <https://www.fda.gov/media/137290/download>
8. Mao L, Jin H, Wang M, et al. Neurologic manifestations of hospitalized patients with coronavirus disease 2019 in Wuhan, China. *JAMA Neurol*. 2020;77(6):683-690. doi:10.1001/jamaneurol.2020.1127
9. Helms J, Kremer S, Merdji H, et al. Neurologic features in severe SARS-CoV-2 infection. *N Engl J Med*. 2020;382(23):2268-2270. doi:10.1056/NEJMc2008597
10. Kandemirli SG, Dogan L, Sarikaya ZT, et al. Brain MRI findings in patients in the intensive care unit with COVID-19 infection. *Radiology*. 2020;201697. doi:10.1148/radiol.2020201697
11. Varga Z, Flammer AJ, Steiger P, et al. Endothelial cell infection and endotheliitis in COVID-19. *Lancet*. 2020;395(10234):1417-1418. doi:10.1016/S0140-6736(20)30937-5
12. Hanidziar D, Bittner E. Sedation of mechanically ventilated COVID-19 patients: challenges and special considerations. *Anesth Analg*. 2020. doi:10.1213/ANE.0000000000005132